

Extraordinary dental findings in an Egyptian mummy skull by means of Computed Tomography

Harbort, J.¹, Ö. Gürvit², L.A. Beck¹, T. Pommerening^{3*}

¹ Department of Biology, Zoological Collection, Philipps University, 35039 Marburg, Germany

² Department of Diagnostic Radiology, Philipps University Hospital, 35039 Marburg, Germany; present address: Department of Neuroradiology, Otto-von-Guericke-University, 39120 Magdeburg, Germany

³ Department of Pharmacy, Institute for the History of Pharmacy and Department of Philology, Egyptology, Philipps University, 35039 Marburg, Germany; present address: Institute for Egyptology and Oriental Studies, FB 07, Johannes Gutenberg-University, 55099 Mainz, Germany

*Corresponding Author: T. Pommerening: tpommere@uni-mainz.de

ISSN 1567-214X

8 figures

Abstract

An ancient Egyptian mummy skull from the Zoological Collection Marburg, Germany, was examined using computer assisted tomography. In this skull (referred to as Mummy skull no. 24) of a man who lived circa 50 BC we found three of his teeth in the cranial cavity. They had been retained after their loss caused by periodontal disease, and were inserted into the cranial cavity via a trans-sphenoidal hole, probably during the process of mummification.

In this article we describe the reasons for the loss of these three teeth and consider possible motivations for this extraordinary conservation. We believe this is the first time such a procedure has been reported. It is discussed in an historical-religious context, emphasizing the mythological background.

Furthermore, the medico-pharmaceutical methods to cure periodontal disease are described with reference to the ancient Egyptian medical papyrus Ebers - in the case of Mummy skull no. 24 one of the causes of loss of teeth.

Key-words: ancient Egypt, Apis embalming ritual, *Apium graveolens*, computed tomography, mummy skull, papyrus Ebers, papyrus Brooklyn 47.218.48, periodontosis, preservation of teeth, tooth loss

Contents:

1. Introduction
2. Materials and methods
3. Results
 - 3.1. Osseous findings
 - 3.2. Dental findings
4. Discussion
 - 4.1. Reasons for teeth loss of the upper left premolars and first molar
 - 4.2. Possible reasons for the exceptional preservation of teeth in the skull
5. Acknowledgements
6. Cited literature

1. Introduction

“A mummy can be a scientific treasure chest; to unlock its secrets, a multidisciplinary approach is needed” (Cockburn *et al.*, 1975: 1155). Following this guideline fifteen Egyptian mummy skulls, as yet unpublished, were examined in an interdisciplinary manner using non-invasive and non-destructive methods - in particular computed tomography (CT) - to determine special embalming practices, pathological changes and the possible causes of death (Harbort, 2003). Since about 1880 AD these mummy skulls have been part of the Zoological Collection of the Philipps-Universität Marburg. Their provenance cannot be precisely determined, but all of the skulls are of Egyptian origin. Identification labels assign their origins to Western Thebes, Abydos, Philae and Saqqara.

Amongst the many findings were pathological degradations of the cranial bone of an old woman, diagnosed as plasmocytoma, and a trauma to the cranial bone of a child which was the probable cause of death (Harbort, 2003). This paper concentrates on the most significant case of the Marburg Mummy skulls, Mummy skull No. 24, and its extraordinary dental evidence.

2. Materials and methods

The item in the Zoological Collection of the Philipps-Universität Marburg presently described here is ‘Mummy skull no. 24’ (figure 1). The original identification label establishes its origin in Western Thebes.



Figure 1. Left lateral view of Mummy skull no. 24. Wrappings and skin are in good condition but show some slight insect attack. Photograph by J. Harbort.

Initially, the skull was subjected to a careful macroscopic inspection. With the exception of an area near the left side of the neck and lower jaw, the skull is fully wrapped in linen. The skin and wrappings are generally in good condition although some holes on the left side indicate slight insect damage. Additionally, insect remains were found in the five intact cervical vertebrae (figures 3-5). These were determined as Coleoptera, more precisely some larvae and one adult related to the family *Tenebrionidae*.

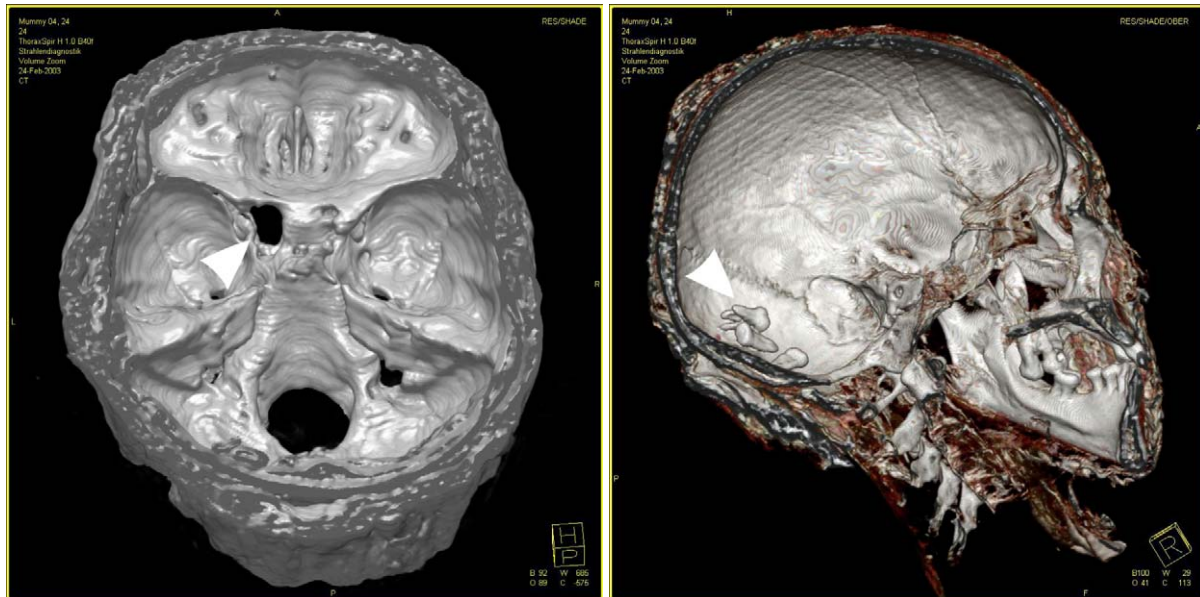


Figure 2 (left). View from superior into the cranium. The trans-sphenoidal hole for brain removal can be seen (arrow). The Lamina cribrosa and the Foramen magnum are not damaged. Photograph by J. Harbort/Ö. Gürvit.
Figure 3 (right). Left part of the skull as a closed cross-section. The position of teeth in the cranial cavity (arrow) and the bad dental state of health is illustrated. Photograph by J. Harbort/Ö. Gürvit.

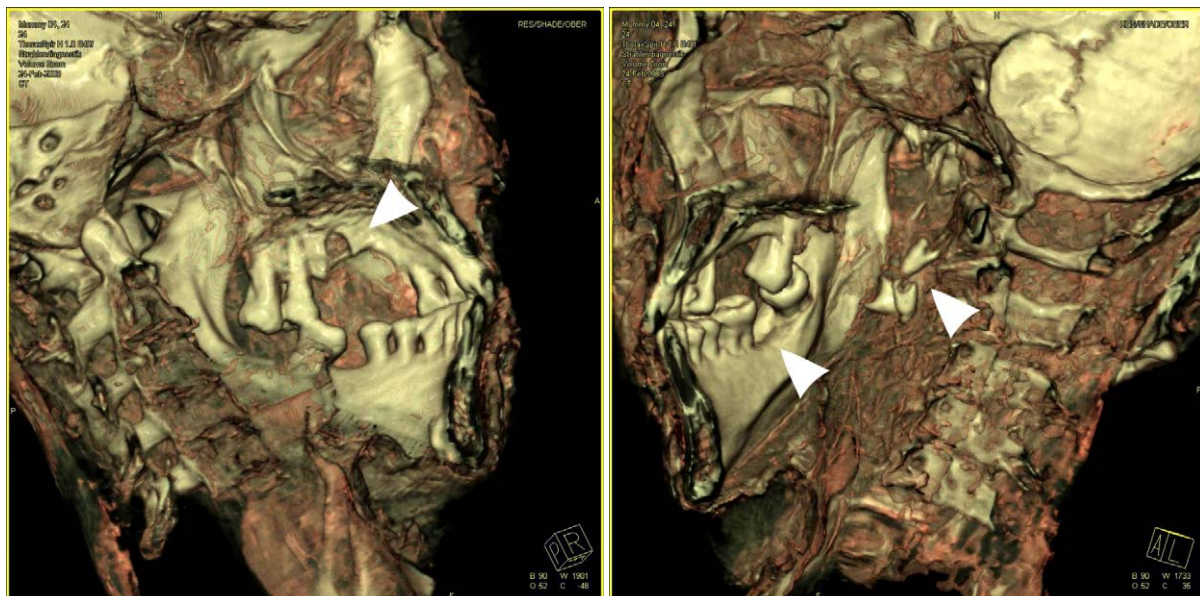


Figure 4 (left). Tooth spaces show open (26) and closed alveoli (24, 25) in the left part of the dentition. Also bone resorption is visible. Photograph by J. Harbort/Ö. Gürvit.
Figure 5 (right). Closed alveole (left arrow) and tooth spaces in the right part of the dentition. Fragments of roots of teeth in the fauces (right arrow). Photograph by J. Harbort/Ö. Gürvit.

The age and sex of Mummy skull no. 24 were determined by dental condition (Miles, 1963) and craniometric measurements (Ferembach *et al.*, 1979; Knußmann, 1996). It is the skull of a 25-35 year old man.

The use of radiocarbon dating applied to the spinal bone (Leibniz-Laboratory for Radiometric Dating and Stable Isotope Research, Kiel, Germany) determined death at 23 BC +/- 22, during the early Roman Period (30 BC-395 AD). Further examination was conducted using computer assisted tomography in the Department of Diagnostic Radiology, Philipps University Hospital, Marburg. 3D-visualization was obtained by volume rendering technique using a multislice computer tomography scanner (Somatom + 4, Siemens, Erlangen).

3. Results

3.1. Osseous findings

A trans-sphenoidal hole (ca. 1.0-1.2 cm diameter) had been drilled via the nose into the left part of the sphenoid bone (figure 2), indicating a crude technique of brain removal during the mummification process. The brain was usually removed via a trans-ethmoidal access created by pushing a metal rod of about 30 cm length and 0.4 to 0.8 cm diameter (Janot, 2000) through the *Lamina cribosa* or it was removed through the *Foramen magnum* (Aufderheide, 2003, 2004). Both are undamaged in this case. No embalming agents were detected in the excerebrated skull (figure 3).

3.2. Dental findings

Generally, the dental condition of Mummy skull no. 24 was poor. As shown in the dental overview (figure 8), some affected teeth are present. Caries was detected on four teeth (15, 26, 27, and 34), and the mesial necks of teeth 15 and 27 are heavily damaged (figures 6 and 7). Significantly, excessive abrasion was not detected despite this being prevalent in Egyptian human remains 1000 years earlier than skull no. 24 (Harris & Wente, 1980; Nerlich *et al.*, 2000a).

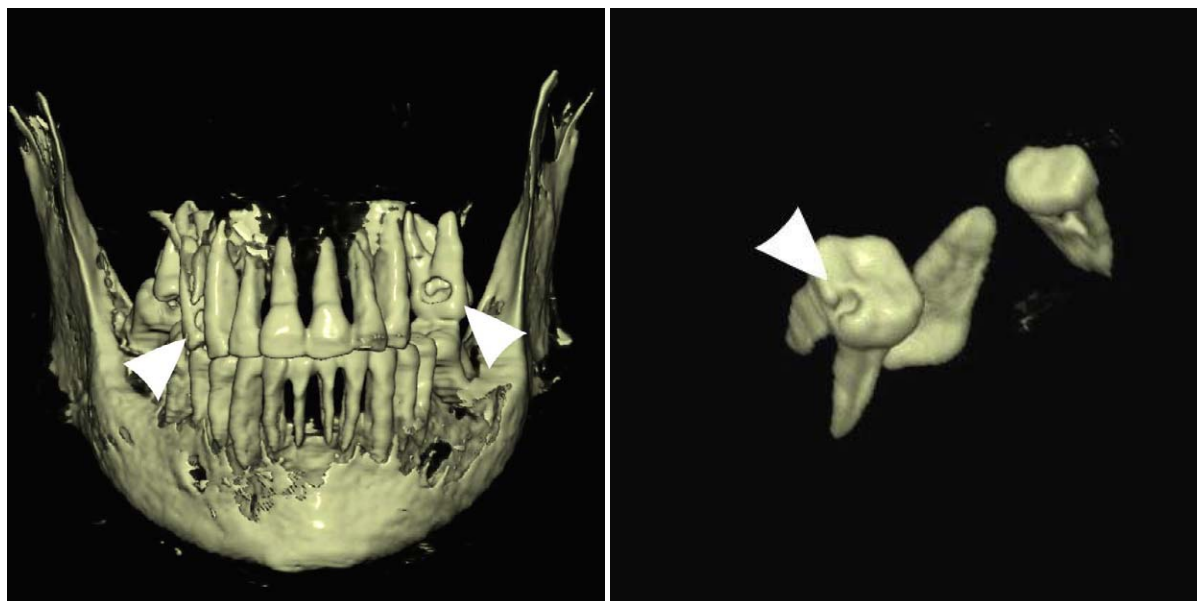


Figure 6 (left). Mummy no. 24 frontal reconstruction of dentition. Notable damaged mesial neck of teeth 15 and 27 due to caries (arrows). The seemingly bad condition of the jaw-bone is a result of computer reconstruction - there is no need for a pathological interpretation. Photograph by J. Harbort/Ö. Gürvit.

Figure 7 (right). Three teeth in the cranial cavity of mummy skull no. 24 (isolated reconstruction). Coronal caries on the first molar is shown (arrow). Photograph by J. Harbort/Ö. Gürvit.

A number of teeth (16, 17, 24, 25, 36, 37, 46, and 48) were lost ante mortem, as demonstrated by closed alveoli (figures 4 and 5). Only the upper left first molar (26) appears to have been lost post mortem, during the embalming process. In this instance the alveole is open (figure 4). The missing teeth 24, 25, and 26 (upper left premolars and first molar) were found loose in the cranial cavity. With the exception of caries on the crown of the molar, these three teeth are in good condition (figure 3). Additional fragments, which were found in the fauces, were identified as partial roots of former unidentified lost teeth (figure 5). Specifically in the area of the left upper molars, bone resorption is visible (figure 4).

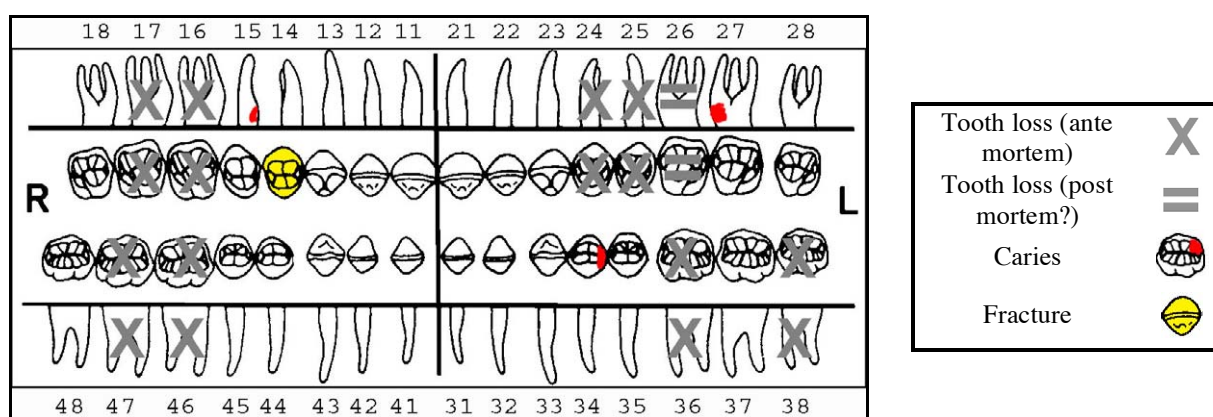


Figure 8. Dental state of Mummy skull no. 24. Dental numerations follow the German dental system. The legend contains the symbols for tooth loss, caries and fractures. Figure by J. Harbort.

4. Discussion

4.1. Reasons for teeth loss of the upper left premolars and first molar

We have demonstrated the poor dental state of Mummy skull no. 24 owing to the loss of teeth and prevalence of caries. Generally, caries was rare before the New Kingdom (1550-1070 BC) but became more common in the Third Intermediate period (1070-715 BC), Late period (715-332 BC) and Greco-Roman period (332 BC-395 AD) (David, 2000; Miller, 2003, 2005; Nerlich *et al.*, 2000a). This may be attributed to a change in nutrition (Bardinet, 1990; David, 2000; Miller, 2003). Nevertheless, caries has only been detected on tooth 26, whilst teeth 24 and 25 in the cranial cavity show no significant damage due to disease or treatment, which would have resulted in dental loss. No evidence of abscesses was found. Moreover, trauma can be ruled out as this would have destroyed the teeth before complete loss, or fractured the jaw. It is more likely that periodontal disease, which was widespread in ancient Egypt (Harris *et al.*, 1998; Leek, 1979; Miller, 2003; Smith, 1986), initiated bone resorption around the teeth (figure 4). This then led to the loss of teeth.

The three teeth in question had obviously been carefully retained, since they had been preserved for mummification. After death and during the embalming process, they must have been placed in the cranial cavity via the trans-sphenoidal access. To our knowledge, this is the first occurrence of this procedure. The teeth described had not apparently been re-used in the owner's life. The closed alveoli made any replacement of the teeth with roots impossible. Furthermore, all dental prostheses found in Egypt (Bardinet 1990; Harris *et al.* 1975) are considered to be constructed for the afterlife (Hoffman-Axthelm, 1976; Nerlich *et al.*, 2000b).

The high incidence of periodontal disease in ancient Egypt is supported by more than just archaeological sources. The Ebers papyrus contains more than 800 remedies, one of which describes the symptoms which are recognised today as periodontal disease: "Another (remedy) to fix the teeth and to treat them. Celery (*matet*) 1, *duat*-plant 1, sweet beer 1, to be chewed; to be spat out to the ground" (Papyrus Ebers, No. 748, ed. Grapow, 1958). Other recipes (Papyrus Ebers, Nos. 754, 755, 746, and 747) also describe characteristic symptoms which typically accompany periodontal disease, but they focus on the treatment of an abscess (Bardinet, 1990).

The title of Papyrus Ebers No. 748 shows that the teeth are loose and that the treatment by drugs was expected to fix them. This mobility indicates periodontal disease. Unfortunately, the identity of the plant described as *duat* remains unknown, so it is impossible to determine whether the remedy would have been effective. *Matet* is used in three dental remedies. Its translation as celery (*Apium graveolens*) (Aufrère, 1986) is convincing, and is supported by the fact that several remains of this plant were found in graves (De Vartavan & Asensi Amorós, 1997). The idea of using it especially for teeth may have arisen from its fleshy, big, and strong stem. By chewing it, the Egyptians may have believed that the same ingredients which strengthened the stem would also fix the tooth. By spitting the mixture to the ground they ejected the teeth-like plant now rid of magical (and perhaps pharmacological) power instead of their own teeth. Examining the pharmacological potential of *Apium graveolens* today, it exhibits anti-inflammatory properties and antibacterial and antifungal activity as it has been shown to contain bioactive aliphatic C17-polyacetylenes (Christensen & Brandt, 2006).

Had the owner of Mummy skull no. 24 taken this remedy in life, it would not have prevented his loss of teeth. However, the preservation and safe retention of the lost teeth during life, permitted the final reinstatement in the upper jaw, so he could hope to regain their full use in his afterlife.

4.2. Possible reasons for the exceptional preservation of teeth in the skull

In the Greco-Roman Period (332 BC-395 AD) mummification was widespread, and varied according to the social background of the deceased, the embalmer's technical skill and local developments (Pommerening, 2007). In all, the external appearance of the mummy was important. This frequently obscured the fact that internally, beneath the bandages, soft tissue preservation had not been achieved, the skeleton often having been rearranged (Aufderheide, 2004), or parts of the body having been replaced by packing material (Aufderheide, 2003; Brech-Neldner & Budde, 1992).

An extensive investigation of human material from the Greco-Roman Period necropolises at Qasr Douch in the Kharga oasis (Lichtenberg, 1996) and Kellis in the Dakhla oasis has been undertaken (Aufderheide, 2004). Further investigations should increase our knowledge of the wide range of mummification techniques of this time. The quest to find further cases comparable to Mummy skull no. 24 is one of the present paper's aims, as only two other incidences of post mortem teeth insertion - none of which occurred in the cranium - are known so far. Both these mummies can be dated to the Greco-Roman period also, affording a religious comparison. In Mummy no. 1770 from the Manchester Museum a human canine tooth was found in the bandages of the right leg (David & Archbold, 2001; David, 1979). Whether it was deliberately placed there or accidentally during a poorly performed mummification, is uncertain. More pertinent in this context is Mummy no. 20.2.1.4 found in Qasr Douch (Kysis). In the pharyngo-larynx of this seven year old child, radiology detected two teeth of an adult (Lichtenberg, 1996).

The Apis embalming ritual (Papyrus Vindobonensis 3873, rt II 12; Vos, 1993) describes a procedure for the removal of two teeth of the divine, dead Apis bull and their replacement by two others (which ones is not specified). This has been interpreted as a ritual re-enactment of the shedding of the milk teeth, understood as Apis' passage towards young adulthood. Therefore, the additional teeth in Mummy no. 20.2.1.4 should be interpreted as magical. Thus the child, as well as the Apis bull, was expected to be reborn at the stage of young adulthood. During the embalming process, the ancient Egyptians re-enacted their myths in rituals, preparing the mummy for the afterlife in a similar fashion as Osiris whose fate was the model for successful mummification (Assmann, 2001; Pommerening, 2007).

What was the purpose of placing this individual's own teeth not in the oro-pharyngeal region, but in the cranium, where we only could find partial roots of some other teeth not entirely having been preserved for the afterlife? Noting that before their loss, the three teeth in question belonged to the skull's upper jaw, and supposing that the said roots belonged to his lower jaw, we may conclude (Papyrus Brooklyn 47.218.48+85, 2,19-26 [No 41]; Sauneron, 1990) that in this case no insertion of teeth occurred but teeth were sowed in order that they could grow through the jaws, the intention being no dental substitute, but actual new teeth. Furthermore, the process of growing permanent teeth in the afterlife placed the deceased in the beginning of adulthood.

5. Acknowledgements

We wish to express our sincere thanks to members of the Diagnostic Radiology, Philipps University Hospital, in particular Prof. Dr. K. J. Klose, and Dr. C. Georg. Special thanks to John Campbell, PhD., Manchester, for correcting our English. We thank the two anonymous reviewers, provided for by the PalArch Foundation, for their suggestions and remarks.

6. Cited literature

- Assmann, J. 2001. *Tod und Jenseits im alten Ägypten*. - München, C.H. Beck.
- Aufderheide, A.C. 2003. *The scientific study of mummies*. - Cambridge, Cambridge University Press.
- Aufderheide, A.C. 2004. Mummification practices at Kellis site in Egypt's Dakhleh Oasis. - *Journal of the Society for the Study of Egyptian Antiquities* 31: 63-86.
- Aufrère, S. 1986. Études de lexicologie et d'histoire naturelle VIII-XVII: Remarques au sujet des végétaux interdits dans le temple d'Isis à Philae - *Bulletin de l'Institut français d'archéologie orientale* 86: 1-32, esp. 9f.
- Bardinet, T. 1990. Dents et mâchoires dans les représentations religieuses et la pratique médicale de l'Égypte ancienne. - Roma, Editrice Pontificio Istituto Biblico (Studia Pohl Series maior; 15).
- Brech-Neldner, R. & D. Budde. 1992. *Der Mumiansarkophag des Nes-pa-kai-schuti*. - Detmold, Topp und Möller.
- Christensen, L.P. & K. Brandt. 2006. Bioactive polyacetylenes in food plants of the Apiaceae family: occurrence, bioactivity and analysis. - *Journal of Pharmaceutical and Biomedical Analysis* 41, 3: 683-693.

- Cockburn, A., R.A. Baracco, W.H. Peck & T.A. Reyman. 1975.** Autopsy of an Egyptian mummy. - *Science* 187: 1155-1160.
- David, A.R. Ed. 1979.** The Manchester Mummy Project: multidisciplinary research on ancient Egyptian mummified remains. - Manchester, Manchester University Press.
- David, A.R. 2000.** Mummification. In: **Nicholson, P.T. & I. Shaw. Ed. 2000.** Ancient Egyptian materials and technology - Cambridge, Cambridge University Press: 372-389.
- David, A.R. & R. Archbold. 2001.** Wenn Mumien erzählen. - München, Heyne.
- Ferembach, D., I. Schwidetzky & M. Stloukal. 1979.** Empfehlungen für die Alters- und Geschlechtsdiagnose am Skelett. - *Homo* 30: 1-32. (in english in *Journal of Human Evolution*).
- Grapow, H. 1958.** Die medizinischen Texte in hieroglyphische Umschreibung autographiert. - Berlin, Akademie Verlag (Grundriß der Medizin der Alten Ägypter; 5).
- Harbort, J. 2003.** Archäometrische und paläopathologische Untersuchungen an altägyptischen Mumien Schädeln der Zoologischen Sammlung Marburg. - Marburg, unpublished diploma thesis.
- Harris, J., Z. Iskander & S. Farid. 1975.** Restorative dentistry in ancient Egypt: an archaeological fact. - *Journal of the Michigan Dental Association* 57: 401-404.
- Harris, J.E. & E.F. Wente. 1980.** Dental disease in the royal mummies. In: **Harris, J.E. & E.F. Wente. Eds. 1980.** An X-ray atlas of the royal mummies. - Chicago, University of Chicago Press: 328-345.
- Harris, J.E., P.V. Pontiz & B.K. Ingalls. 1998.** Dental health in ancient Egypt. In: **Cockburn, A. & E. Cockburn. Eds. 1998.** Mummies, diseases and ancient cultures. - Cambridge, Cambridge University Press: 15-58.
- Hoffman-Axthelm, W. 1976.** Zahnprothetik im alten Ägypten: eine archäologische Tatsache? - *Quintessenz* 11: 155-163.
- Janot, F. 2000.** Les instruments d'embaumement de l'Égypte ancienne. - Cairo, Institut français d'archéologie orientale du Caire.
- Knußmann, R. 1996.** Vergleichende Biologie des Menschen. Lehrbuch der Anthropologie und Humangenetik. - Stuttgart, Fischer.
- Leek, F.F. 1979.** The dental history of the Manchester mummies. In: **David, A.R. Ed. 1979.** The Manchester Mummy Project: multidisciplinary research on ancient Egyptian mummified remains. - Manchester, Manchester University Press: 65-77.
- Lichtenberg, R. 1996.** La momification en Egypte à l'époque tardive. In: **Temporini, H. & G.G.W. Haase. Eds. 1996.** Aufstieg und Niedergang der Römischen Welt, vol 37.3. - Berlin, De Gruyter: 2741-2760.
- Miles, A.E.W. 1963.** Dentition in the assessment of individual age in skeletal material. In: **Brothwell, D.R. Ed. 1963.** Dental anthropology. - Oxford, Pergamon: 255-263.
- Miller, J. 2003.** An appraisal of the skulls and dentition of ancient Egyptians, highlighting the pathology and speculating on the influence of diet and environment. - Manchester, Faculty of Medicine, unpublished Ph.D. Thesis.
- Miller, J. 2005.** Dental health in ancient Egypt. In: **Rabino Massa, E. Ed. 2005.** Proceedings V World Congress on Mummy Studies. - Turin, Italy Compagnia di San Paolo (*Journal of Biological Research* Vol. LXXX, N.1): 117-120.
- Nerlich A.G., A. Zink, H.G. Hagedorn, U. Szeimies & C. Weyss. 2000a.** Anthropological and palaeopathological analysis of the human remains from three "Tombs of the Nobles" of the necropolis of Thebes-west, upper Egypt. - *Anthropologischer Anzeiger* 58, 4: 321-343.
- Nerlich, A.G., A. Zink, U. Szeimies & H.G. Hagedorn. 2000b.** Ancient Egyptian prosthesis of the big toe. - *Lancet* 356, 9248: 2176-2179.
- Pommerening, T. 2007.** Mumien, Mumifizierungstechnik und Totenkult im Alten Ägypten - eine chronologische Übersicht. In: **Wieczorek, A., M. Tellenach & W. Rosendahl. Eds. 2007:** Mumien - Der Traum vom ewigen Leben. - Mainz, Philipp von Zabern: 71-88.
- Sauneron, S. 1990.** Un Traité Égyptien d'Ophiologie. Papyrus du Brooklyn Museum No 47.218.48 et .85. - Cairo, Institut français d'archéologie orientale du Caire (Bibliothèque Générale; XI).
- Smith, N.J.D. 1986.** Dental pathology in an ancient Egyptian population. In: **David, A.R. Ed. 1986.** *Science in Egyptology: The Proceedings of the 1979 and 1984 Symposia*. - Manchester: 43-48.
- Vartavan, de, C. & V. Asensi Amorós. 1997.** Codex of ancient Egyptian plant Remains. - London, Triade Exploration.
- Vos, R.L. 1993.** The Apis embalming ritual: P. Vindob. 3873 - Leuven, Peeters (*Orientalia Lovaniensia Analecta* 50).

Submitted: 14 September 2007

Published: 3 January 2008

About www.PalArch.nl (Netherlands scientific journal) copyright.

Copyright © 2008 PalArch Foundation

The author retains the copyright, but agrees that the PalArch Foundation has the exclusive right to publish the work in electronic or other formats. The author also agrees that the Foundation has the right to distribute copies (electronic and/or hard copies), to include the work in archives and compile volumes. The Foundation will use the original work as first published at www.PalArch.nl.

The author is responsible for obtaining the permission of the use of illustrations (drawings, photographs or other visual images) made by others than the author. The author can be requested to submit proof of this permission to the PalArch Foundation. Pdf texts (papers and proceedings) are free to download on the conditions that each copy is complete and contains the PalArch copyright statement; no changes are made to the contents and no charge is made. The downloaded (and/or printed) versions of PalArch publications may not be duplicated in hard copy or machine readable form or reproduced photographically, nor may they be redistributed, transmitted, translated or stored on microfilm or in electronic databases other than for single use by the person that obtained the file. Commercial use or redistribution may only be realised after consultation with and with written permission of the PalArch Foundation.